

# CANBERRA Equine HOSPITAL

## TENDON INJURIES

Tendons are the strap-like structures that attach muscles to the bones on which they act. Most tendons are short and rarely damaged. However, the long tendons of the limbs are very vulnerable to damage during exercise or as a result of direct trauma. The flexor tendons are most important and it is these that are discussed below.

### *Where are the tendons situated?*

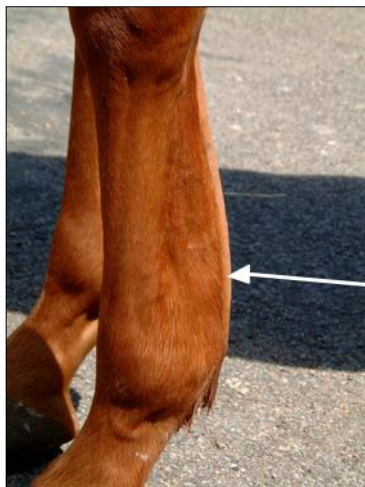The flexor tendons (deep digital flexor tendon, DDFT, and superficial digital flexor tendon, SDFT) run down the back of the leg from the level of the knee (or hock). The SDFT ends on the pastern, the DDFT ends on the lower surface of the pedal bone. At the back of the knee, in the region of the hock and at the level of the fetlock and upper pastern, the tendons are enveloped by a fluid filled sheath. Several strong, short, annular ligaments help to keep the tendons in place in areas of high movement such as joints.



Veterinarian examining a horse's tendon for signs of injury.

The tendons themselves are composed of longitudinally arranged bundles of fibres. Blood supply to tendons is poor compared to muscles and other tissues.

### *What are the different types of tendon injury?*



*A 'bowed' tendon (arrowed)*

Picture courtesy of M J Head,  
Rossdale & Partners.

Damage to flexor tendons occurs commonly during exercise. Moderately strenuous exercise can result in tearing of fibres in horses that are not fit. Even in fit horses, over stretching of tendons can occur during fast work, work on unlevelled ground or work involving jumping at speed. The degree of damage can range from minor, with little fibre damage to very severe with total tendon rupture occurring.

Most often, a proportion of fibres damaged resulting in a zone of damaged fibres within the body of the tendon. This might form a discreet "hole" which extends for a variable length of the tendon.

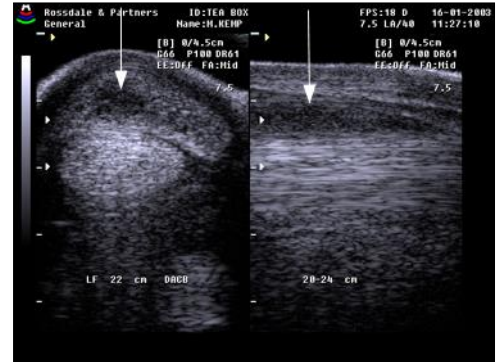
A knock to a tendon may result in slight bruising or more severe damage possibly even tendon rupture. Sharp trauma such as a cut can also result in anything from minor damage to severing of the tendon. Injuries involving tendon sheaths are very serious as infection in these structures is potentially life threatening.

### ***What are the first signs of tendon injury?***

Damage to a tendon causes inflammation, heat and swelling. Minor fibre damage leads to slight enlargement of the affected part which will feel warmer than the corresponding area on the other limb. Mild strains do not cause lameness. In severe damage, the limb may become very painful and swollen and the horse may be severely lame. If the tendon is ruptured, the horse may walk with the toe tipped up. If a tendon sheath becomes infected, the horse will also be very lame.

### ***How can tendon injuries be diagnosed?***

If you suspect that your horse has a tendon injury, you should call your veterinarian. A clinical examination will confirm or wipe out your concerns. Your vet will look for signs of thickening of the affected tendon(s), heat, pain on palpation etc. It can be difficult to assess the extent of damage by look and feel alone. Ultrasonographic examination – tendon scan – allows visualization of the structure of the tendon and any damage. It also allows assessment of healing processes.



Ultrasound images of a horse's tendon injury (arrowed).

Picture courtesy of M C Shepherd, Rosedale & Partners.

### ***What treatments are available?***

There are several treatments for tendon injuries but none is guaranteed to result in permanent soundness. Damaged tendon heals by producing irregularly arranged fibres. This repair is weaker than normal tendon and re-injury is common. In the early stages anti-inflammatory treatment such as the application of cold, support bandaging, Phenylbutazone etc. is useful. Rest is vital. Your veterinarian will advise whether total box rest is required. Turning a horse out into a paddock is not resting its tendon. Most tendon injuries require at least 3 months of restricted exercise (e.g. walking in hand or on a horse walker). Repeat tendon scans are invaluable for assessing healing before exercise levels are increased. In many horses, it is a year before they are fit to compete again.

Attempts have been made to speed up healing and to improve the quality of the repair tissue by injection substances into the tendon itself. Most recently BAPTN has been used with some success. Tendon “splitting” is recommended by some veterinarians. Small cuts are made into the damaged area to allow drainage of inflammatory fluid. Time for repair is not reduced.

Tendon firing is a contentious subject. In spite of scientific evidence that it does not enhance healing and is in fact inhumane, firing is still widely performed. A hot iron is applied to the skin to burn through into the damaged tendon to provoke a healing response. The leg invariably swells and is quite painful.

“Blistering” is the application of an irritant chemical to the skin to provoke inflammation. It is a widely used practice but does not have scientific support. You can discuss these treatments with your own veterinarian.

After a period of rest your horse should be introduced to a gradually increasing program of exercise which should eventually include trotting and very steady cantering. You may not be able to return to as high a level of competition as before the injury but most horses can lead a useful life as a hack or even hunter after tendon injury.